

NOTES

Technical Aspects - Hype or Hope?

HUBERTUS FEUSSNER, M.D.^{1,3}
PHYSICIAN

DIRK WILHELM, M.D.^{1,3}
PHYSICIAN

ADAM FOLKA, M.Sc.³
ENGINEER

ALEXANDER MEINING, M.D.²
PHYSICIAN

SALMAN CAN, M.Sc.³
ENGINEER

ARMIN SCHNEIDER, M.Sc.³
ENGINEER

HELMUT FRIESS, M.D.¹
PROFESSOR OF SURGERY

¹DEPARTMENT OF SURGERY, KLINIKUM RECHTS DER ISAR DER TUM

²DEPARTMENT OF GASTROENTEROLOGY, KLINIKUM RECHTS DER ISAR DER TUM

³WORKING GROUP, "MINIMALLY INVASIVE INTERDISCIPLINARY THERAPEUTIC INTERVENTION" (MITI)
MÜNCHEN, GERMANY

ABSTRACT

Natural orifice transluminal endoscopic surgery (NOTES) is currently an intensely discussed topic. The debate is extremely controversial, ranging from euphoric visions to complete refusal, and the future clinical role of natural orifice surgery is difficult to describe. This chapter analyzes the current technological status, and addresses the question of whether the surgical procedures will become an option. A literature research was undertaken using Medline and Pubmed. Personal experiences and communications were also included in this state-of-the-art report. The individual barriers currently impeding the clinical use, as defined by the NOSCARG group, are addressed in detail. With the exception of the vaginal access, no natural orifice-entering technique is already clinically mature. The selective use-potentially in combination-in a more refined technique than currently, is likely to provide a breakthrough. Most of the remaining obstacles are just a matter of further progress in advanced medical engineering. However, it should not be forgotten that the problems to be solved are less than trivial, and close cooperation between engineers and surgeons is essential. NOTES is still in the early stages of development. Currently available tools and techniques remain in the pioneer stage. However, worldwide activities in research and development will lead to promising solutions, which certainly will help to overcome the existing barriers. Whether "pure NOTES" or hybrid procedures only, surgery will take another step forward toward a less-invasive discipline.

INTRODUCTION

Less than 20 years ago, laparoscopic surgery emerged to minimize the operative trauma and improve the surgical outcome. After about 15 years of minimally invasive surgery, the next, even less-invasive surgical concept of natural orifice transluminal endoscopic surgery (NOTES) was developed to avoid even the tiny scars that result from laparoscopic interventions.

NOTES began in the animal laboratory with a landmark study published by Kalloo and colleagues. They described a simple transgastric peritoneoscopy with liver biopsy in a porcine survival model.¹ In a short period of time, many additional papers were published that demonstrated the feasibility of even more complex procedures, such as cholecystectomy, appendectomy, lymphadenectomy, and others (Table I) (Fig. 1).

It did not take long that the first human "NOTES cases" were performed as well (Table II). However, only a few were "true" NOTES interventions according to the definition of

NOTES by Baron and coworkers²: "NOTES implies surgery performed endoscopically by initially passing the endoscope transorally or transanally, then transluminally into areas that would not otherwise be accessible endoscopically."

In the majority of cases, current clinical reports deal with "pseudo NOTES" procedures. It has to be emphasized that the use of a transvaginal approach had already been established, such as for removal of gallbladders with large stones and of the specimen after laparoscopic splenectomy.^{3,4}

Obviously, the hurdles to perform "real NOTES" are still too high to introduce this new surgical concept into clinical routine. The relevant barriers for NOTES have already been identified and named rather early in the short history of NOTES by a working group known as NOSCART (Natural Orifice Surgery Consortium for Assessment and Research) (Table III).⁵ They comprehend both medical and technological challenges, but the latter clearly prevail.

The aim of this Chapter is to describe the current status of NOTES and delineate the prospects to overcome the currently valid barriers.

DISCUSSION

Access to Abdominal Cavity

To date, the four different entry sites for natural orifice surgery have been used: transgastric, transcolonic, transvesical, and—in female patients—the vaginal approach. So far, none of them is considered as ideal (Fig. 2).

1. The transgastric route is currently the most popular way to enter the peritoneal cavity. Maneuvering the endoscope within the stomach is comparatively easy, and the degree of contamination is considerably lower than in the colon. Several technical refinements have been published to facilitate the initial gastrotomy, such as the balloon dilatation and PEG technique⁶ or the submucosal tunnelling.^{7,8} However, some abdominal regions, such as the hiatus, are difficult to reach by way of the transgastric access.
2. In female patients, the vagina is a suitable natural orifice for the majority of NOTES procedures. Decontamination is easily achieved and it is little wonder that most human series on NOTES were per-

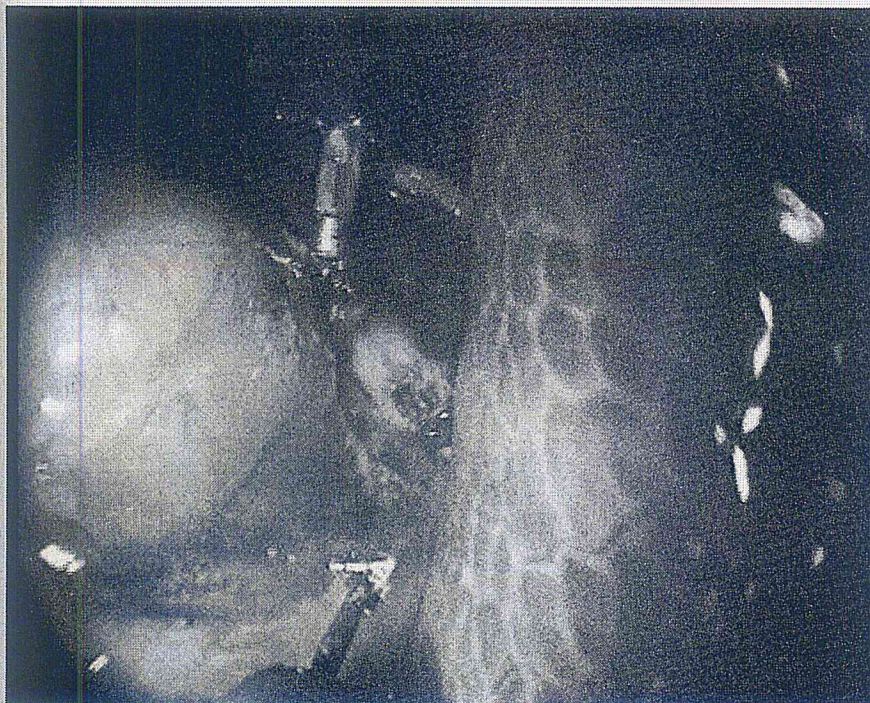


Figure 1. NOTES cholecystectomy in the animal model. The cystic artery and duct are already closed by hemoclips and dissected. After injection of a blue-dyed solution the gallbladder is separated from the liver and dissected by electrocautery.

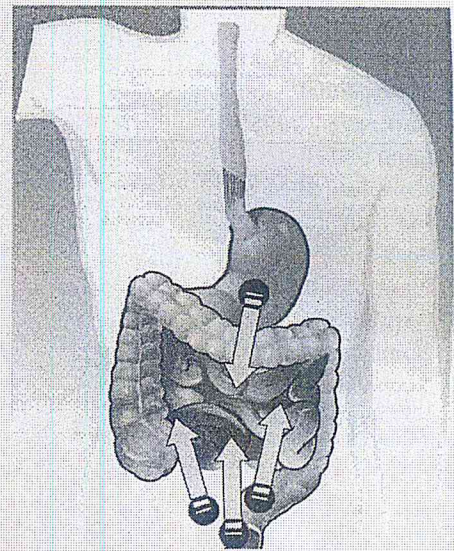


Figure 2. Access to the peritoneal cavity is gained via different routes. The transgastric approach is currently applied the most often, but provides a limited view to upper gastrointestinal organs. Alternatively the abdomen can be entered via a transcolonic, transvesical or transvaginal access. of a blue-dyed solution the gallbladder is separated from the liver and dissected by electrocautery.

formed transvaginally. However, it is only applicable in 50% of the patients, and there remains the concern regarding late complications (eg, dyspareunia).⁹

3. The transvesical access has been used for peritoneoscopy and thoracoscopy.^{10,11} It is the only orifice more or less sterile, and closure of the urinary bladder is safe and easy. The almost exclusive disadvantage is the restricted diameter. Only small-bore instruments (<5-mm) may be used to avoid damage to the urethra and sphincters.
4. The colonic approach is considered as the most problematic one by many authors despite the good viability. The main concerns are bacterial contamination and secondary leakage.

In three series, serious complications occurred in up to 20% of the animals.¹²⁻¹⁴

The authors developed the so-called innovative, safe, and sterile sigmoid access (ISSA).¹²⁻¹⁴ After establishment of a fluidoperitoneum using a Veress needle, the gas-contaminating bowel is separated from the pelvic floor and rectosigmoid. Using transanal ultrasound, an entry point is identified at the anterior rectosigmoid junction in safe distance from the bowel and major vessels. Closure is achieved using a purse string suture and a linear stapler (Figs. 3a & 3b).¹⁵

There will probably be no universal approach for the entire range of NOTES procedures. Imaginable is that the transgastric approach will be preferred for interventions in the lower abdomen, whereas the transvaginal or transanal access is superior for surgeries in the upper abdomen. Most interestingly, own first experience has confirmed that a dual access may be additionally helpful.¹⁶

Prevention of Infection

Prevention of infection is the Achilles heel of NOTES, since the sealed, sterile, peritoneal cavity is entered not through the abdominal wall, which is decontaminated and disinfected easily, but by way of the more-or-less contaminated intestinal lumen.

As compared to the significance of this issue, current knowledge remains scarce. The stomach is usually not contaminated, but as soon as the intragastric pH is raised, bacterial and fungal overgrowth is common.¹⁷ Furthermore, the mouth and pharynx carry a heavy bacterial load and contact with the endoscope is inevitable.

As learned from an early study, NOTES interventions without any gastric preparation or decontamination are followed by a high rate of abdominal micro abscesses.¹ Currently, most authors recommend gastric lavage with or without antibiotics.¹⁸⁻²⁰ One study

Table I
NOTES Animal Survival Studies Conducted to Date

Author/Year	N	Orifice	Intervention (N*)	No. of Surviving Animals	Survival ^{§†} Period (d)
Bergstrom 2006 ³²	12	O	ANA (12)	Y (6)	7-10
Fong 2007 ²⁰	6	A	PER (6)	Y (6)	14
Jagannath 2005 ²²	6	O	FAL (6)	Y (6)	14-21
Kaloo 2004 ²⁵	17	O	BIO (5)	Y (5)	14
Kantsevov 2005 ²²	2	O	ANA (2)	Y (2)	14
Lima 2006 ³¹	8	U	BIO (8)	Y (5)	15
Merrifield 2006 ³²	5	O	OOP, TUB, HYS (5)	Y (5)	14
Pai 2006 ³⁶	5	A	CHO (5)	Y (5)	14
Park 2005 ⁴⁶	16	O	ANA (3); CHO (5)	Y (8)	14-28
Pham 2006 ⁵⁹	10	A	CC (10)	Y (8)	7
Raju 2005 ⁵⁵	5	A	CC (5)	Y (4)	7
Sumiyama 2006 ⁴⁹	5	O	APP (2)	Y (5)	1-2
Sumiyama 2007 ⁵⁰	6	O	MGC (6)	Y (5)	7
Sumiyama 2007 ⁵⁹	4	O	SEMF (4)	Y (4)	7
Wagh 2005 ⁶¹	8 [‡]	O	OOP, TUB, HYS (6)	Y (3)	?1
Wagh 2006 ⁵⁹	6	O	OOP, TUB, HYS (6)	Y (6)	14
Wilhelm 2007 ⁷⁰	8	A	PER (8)	Y (8)	10

*Number of subjects receiving this treatment.

§† Survival refers to monitoring of animals postprocedure for signs of morbidity, mortality, and recovery.

‡1 Cadaver also used.

A, indicates anal; ANA, anastomosis; APP, appendectomy; BIO, biopsy; CC, colostomy closure; CHO, cholecystectomy; FAL, fallopian tube ligation; HYS, hysterectomy; LYM, lymphadenectomy; MGC, multiple gastrotomy closure; O, oral; OOP, oophorectomy; PER, peritoneoscopy; SEMF, submucosal endoscopy with mucosal flap; TUB, tubectomy; U, urethral.

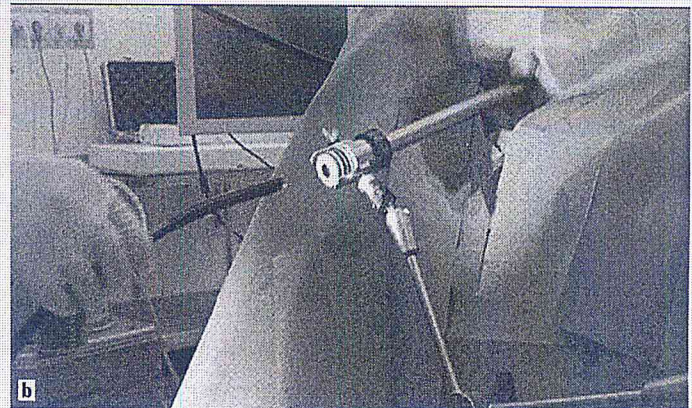
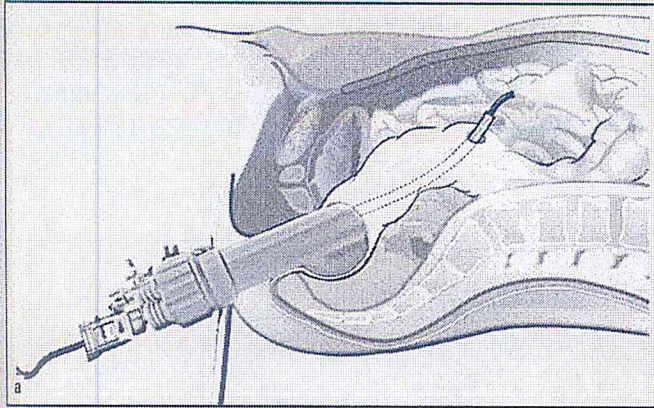


Figure 3a. The ISSA access, as described by our group uses a transcolonic incision and a specially designed trocar system to enter the abdominal cavity. The entrance site is prepared under direct control by means of a modified TEM device. It furthermore allows a leak-proof closure of the entrance by stapler application afterwards.

Figure 3b. Second generation ISSA trocar system in the animal lab. The trocar is mounted to the operation table and guarantees an easy and reliable approach to the abdomen.

demonstrated that povidone-iodine prevented the development of micro abscesses observed in control animals,²¹ but other data that also exist show gastric rinsing with 5 liters of 0.9% saline is also effective.

The transcolonic approach is prepared even more comprehensively. After water enema lavage, iodine or antibiotic solutions are usually instilled and considered to be effective,^{12,22,23} but what the essentials are is difficult to describe. It could be shown, however, that povidone-iodine and quater-

nary ammonium antimicrobial solutions lead to a significant reduction of the amount of colonic flora and prevent postoperative infections/complications.²⁴

In our series, we currently use a mucosal antimicrobial solution (Octenisept[®], Schülke & Mayr, Norderstedt, Germany) after water enemas. In addition, the fluidoperitoneum is established by Taurolidin[®] (Bi Pharma, Ingelheim, Germany).¹⁶ Therefore, the good results obtained encourage us to use the transcolonic

approach more liberally²⁵ (Fig. 4).

Surprisingly, the debate regarding sterility and contamination is completely dominated by the topic of the approach. From the surgeon's point of view, the question of being forced to use instruments and tools that cannot yet be completely sterilized (flexible endoscopes and instruments), is at least troublesome. It is remarkable how little attention has been given to this issue to date.

Nevertheless, NOTES is accompanied by a significant intraperitoneal bac-

Table II
 Human NOTES Cases

Author/Year	N	Population		Orifice	Procedure (N*)	Follow-up Period
		F/M	Age			
Gettman 2007 ²⁴	1	0/1	56	U	PER (1)	2 mo
Hazey 2007 ²⁸	10	NR	67.6 (49-79) [†]	O	PER (10)	NR
Marks 2007 ²⁷	1	0/1	70	O	PER, PEG (1)	30 d
Tsin 2007 ³⁷	3 [‡]	3/0	NR	V	APP (3) [‡]	Up to 2 mo
Burghardt 2008 ³⁰	20	20/0	NR	V	CHO	NR
Forgione 2008 ⁵	3	3/0	48	V	CHO	1 mo
Ramos 2008 ⁷	32	32/0	33	V	CHO	NR
Zornig 2008 ²¹	20	20/0	NR	V	CHO	NR
Zorron 2008 ⁵⁴	4	4/0	35	V	CHO	NR

*Number of subjects who received this treatment.

[†]Mean (range).

[‡]Only 3 appendectomies of the case series of 100 patients were considered for this review.

APP, appendectomy; CHO, cholecystectomy; NR, not reported; O, oral; PEG, "PEG, rescue"; PER, peritoneoscopy; U, urethral.

Table III
Potential Barriers to Clinical Practice for NOTES¹

Potential barriers to clinical practice
Access to peritoneal cavity
Gastric (intestinal) closure
Prevention of infection
Development of suturing device
Development of anastomotic (non-suturing) device
Spatial orientation
Development of multitasking platform to accomplish procedures
Control of intraperitoneal hemorrhage
Management of iatrogenic intraperitoneal complications
Physiologic untoward events
Compression syndromes
Training other providers

terial burden that reaches up to 2.4×10^4 colony-forming units per milliliter,^{19,26} but this becomes scarcely clinically apparent in most cases.²⁷ A careful experimental study upon TNF- α expression showed that despite soiling the peritoneal cavity with luminal microbes and chemical irritants (such as bile and gastric acid), the resultant degree of

measured acute systemic inflammation associated with NOTES appears to be no greater than laparoscopy.²⁸ However, difficult to explain is that the TNF α depression lasted longer than after laparoscopy and open surgery. Additional basic scientific and clinical studies are required to better understand this particular aspect of NOTES.

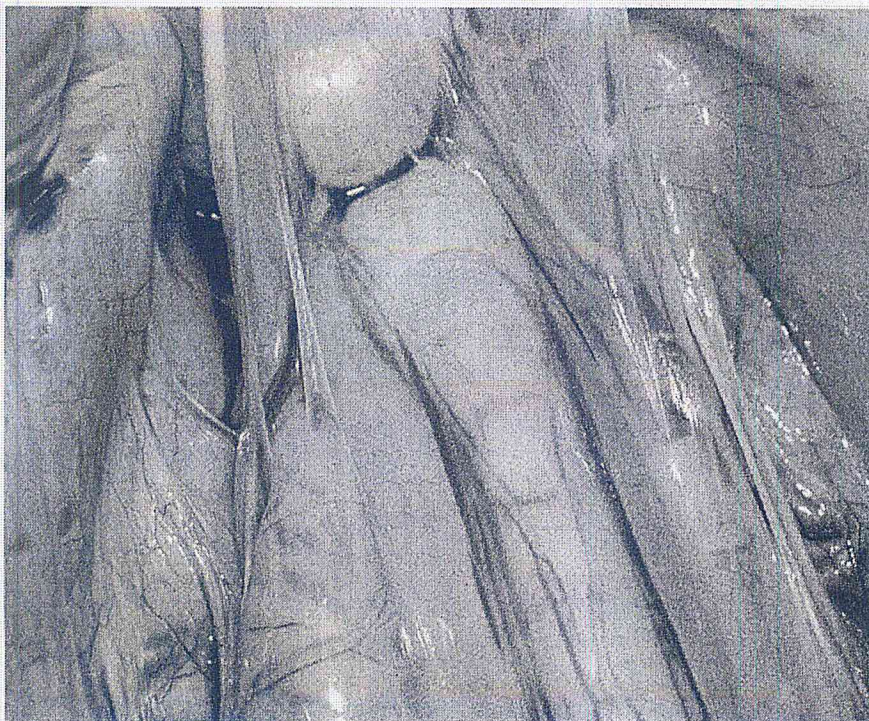


Figure 4. Necropsy results after transcolonic transluminal surgery. Due to the decontaminating agent installed and the secure closure of the entrance no abscesses or adhesions are identified.

Intestinal Closure, Development of Suturing and of Anastomotic (Non-Suturing) Devices

Problem of Viscerosynthesis

NOTES is inevitably linked with at least one perforation: either the vaginal wall, urinary bladder, or gastrointestinal (GI) tract. A reliable closure is a condition sine qua non, in particular, of GI tract incisions. Primary or secondary leakage is a catastrophe and has to be avoided by any means.

Likewise, any full-thickness resection of the GI wall or circumferential sleeve resection requires a reliable technique of viscerosynthesis. Independent of whether only a small incision has to be occluded or a circumferential anastomosis has to be performed, the surgical technique should provide:

- ◆ adequate blood supply
- ◆ lack of tension
- ◆ inclusion of the submucosa
- ◆ air-tight repair

Many devices currently evaluated for NOTES do not yet meet these requirements.

Before the oncoming of NOTES, clips were already used occasionally by Endoscopists to occlude defects of the GI wall. If it is possible to control the wound edges to apply the clips properly, they function rather well. It is doubtful, however, that the safety and applicability are really sufficient for systematic use.

Interesting Innovations

T-fasteners positioned either before or after full-thickness resection are comparatively well-suited to close the defect.²⁹ One of the problems is the laceration of adjacent structures. Well-known alternatives are the G-prox (USGI Medical, San Clemente, CA, USA) or the so-called NDO plicator (company no longer in business).³⁰⁻³² The Endorivet³³ (Fig. 5) and Eagle Claw (Olympus Surgical, Hamburg, Germany)^{34,35} need further functional improvement. All of these systems have in common that they are difficult to apply and time consuming, highly technical, and expensive.³⁶ Recently, the newly developed OTSC³⁰ device (Ovesco, Tübingen, Germany) was presented.³⁷ Further studies are needed to confirm whether it is really more advantageous.

The most reliable and fastest way to achieve viscerosynthesis is the use of staplers. For NOTES' purposes, they need

Table IV
Assessment of Current Gastrointestinal Occlusion Techniques¹⁶

Procedure	Level of Difficulty	Safety	Applicability	Availability	Range of Indications
No Closure	--	--	--	--	Urinary bladder only
Submucosal Tunneling	medium	?	stomach only	exp.	high
Clips	low	Low	high	com. available	medium
Endorivet	medium	High	high	exp.	high
Tie Tag	high	High	high	exp.	high
Eagle Claw	high	High	?	exp.	medium
GI Prox	high	High	?	exp.	high
OTSC	low/medium	High	no lesion	com. Available	high
Plicator	medium	High	?	com. Available	high
Linear Stapler	medium	High	medium	com. Available	medium
Circular Stapler	medium	High	low	com. Available	low

com = commercially; exp = experimental




Figure 5. The Endorivet[®] is a revolutionary modality for endoscopic closure of intestinal incisions or perforations. The rivet is applied via a liberator device and closed by adaptation of implemented plastic cramps. The sharp tip of the rivet is built of magnesium and dissolves autonomous in the acid gastric juice.

to be flexible, and the first examples are already available.²² The first experimental studies were performed to occlude a gastric lesion.³⁸ For a broader range of indications, they have to be miniaturized and the head remotely controlled, including an integrated telescope. A universal and safe technique is not currently available (Table IV).

Spatial Orientation

Endoluminal surgeons and intracavitary surgeons live in different worlds, with a completely different perception of the anatomy. Laparoscopists need, and are accustomed to, an "anatomical horizon." Endoscopists are familiar with the exclusively prograde view to the object and coaxial action of the instruments. The GI lumen, even in the stomach, is comparatively small, which makes illumination and insufflation easy. The field-of-view of modern flexible endoscopes is completely sufficient to perceive the surgical site, and reliable anatomical landmarks are available for spatial orientation. As soon as the GI tract is left and the huge cavity of the abdomen is entered, the working conditions change significantly. It is impossible to achieve an "overview" or panorama view, because of the limited angle of the view, weak illumination, and inadequate position of the endoscope. Spatial orientation has to be gained by a mental synthesis of innumerable single visual segments, which is even more difficult due to the paucity of distinct and stable anatomical landmarks (Fig. 6).

However, it may be expected that computer science will soon be able to make intuitive navigation into the abdominal cavity possible.^{39,40} Augmented reality can be created by using pre-procedure computed tomography (CT) or magnetic resonance imaging (MRI), real-time tracking of the endoscope, and reference image registration, which will be helpful in identifying the optimal perforation site or find the route to the intraperitoneal target.⁴¹

New methods, such as the "time-of-flight", enable engineers to define exactly the spatial position of each single object within the visual field. Surface rendering is, thus, feasible as well as mosaicing the vast number of images taken from various visual segments of the abdomen⁴² and a panorama view is reconstructed. The abdominal cavity is visible in its entirety, far beyond the small segment actually visualized by the endoscope.

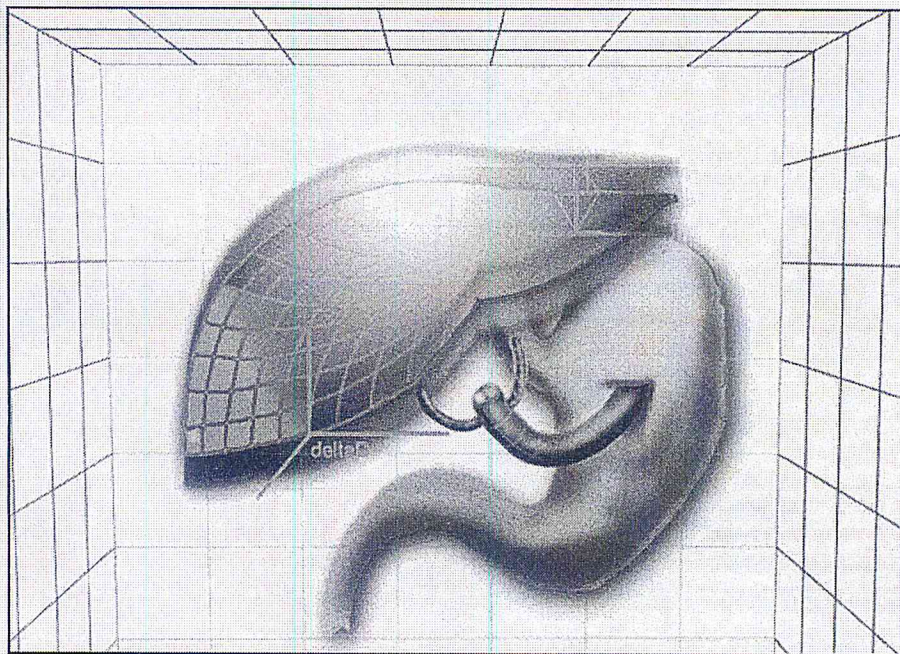


Figure 6. The orientation problem inside the abdominal cavity currently is widely ignored; computer software and intelligent imaging processing potentially might provide supporting ambient information and a virtual reconstruction of the scenery.

Moreover, the precise spatial information is extremely helpful for use of instrumentation platforms by defining "forbidden zones" etc. It may be anticipated that these significant improvements in spatial orientation will make intra-cavitary interventional techniques easier to master and use in clinical practice and, thus, more likely to be widely adopted.

Development of Multitasking Platform to Accomplish Procedures

The trend toward single-port surgery and, in particular, NOTES stimulates the development of new flexible manipulation systems. Currently available laparoscopic instruments or flexible endoscopes are inadequate to

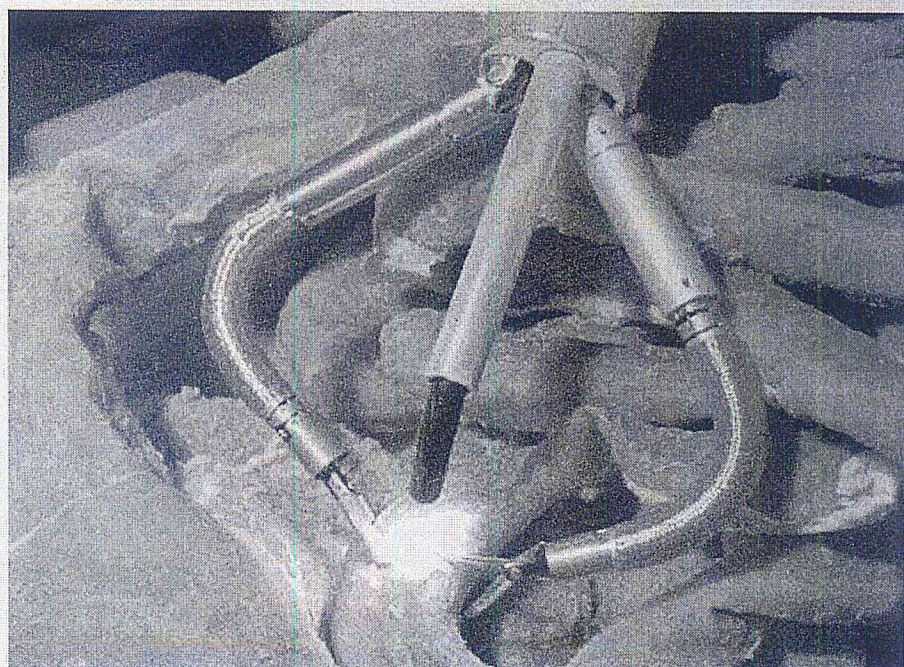


Figure 7. Multitasking platforms, such as the HVSPS®, may transfer the surgeon actions inside the abdominal cavity and therewith facilitate even complex interventions.

perform important maneuvers of manipulating tissues, and to set up traction and counter traction for exposure and division of anatomical structures.

Although a great deal of developmental work remains to be done, building up the hardware is the minor problem. Some systems, such as the Octopus,⁴³ Direct Drive Endoscopic System (DDES),⁴⁴ the miniature robot,³⁵ or our own highly versatile single-port system (HVSPS),⁴⁵ are already in experimental evaluation (Fig. 7).

Serious problems, however, arise as soon as the surgeon or surgical team begin working with mechatronic support systems under clinical conditions. The control of multiple devices and functions is excessively demanding.⁴⁶ It is inconceivable that humans are able to master this task without intelligent support of something like an autopilot in aircraft industry.

Two critical interfaces have to be considered: the interface between anatomy and the machine, and the interface between the machine and the human operator.

The task of computer science and

medical engineering is to provide safety and efficiency of manipulating the tissue with mechanic end effectors by creating automated actions, identifying and avoiding potentially dangerous situations, etc.⁴⁷

Computer science should alleviate the use of these types of complex technical systems by supporting decision-making and offering help to the user in performing the required manipulations. Thus, multitasking platforms will become part of an integrated Operating Room environment, which additionally offers a broad range of functionalities such as spatial orientation, as already mentioned, or automatic workflow analysis and support,^{48,49} and provides the optimal working conditions for NOTES.

Control of Intraoperative Hemorrhage

The control of intraoperative bleeding and reduction of blood loss is a cornerstone of modern surgery. Endoscopic hemostatic techniques, however, are mostly confined to weak surface bleeding (Argon beaming, epinephrine injections, electrocautery, etc). If a distinct vessel can be identified, clips or endoloops can

be applied. However, in general, NOTES techniques to manage acute and heavy bleedings are still limited and rapid conversion to laparoscopic surgery is recommended. However, it is to be expected that both of the two major advances that stimulated the development of laparoscopic surgery so greatly within the last years will soon be adapted for NOTES as well: impedance-guided electrocoagulation and ultrasonic dissection. As soon as miniaturized probes are available, NOTES interventions will be significantly enhanced.

Management of Physiologic Untoward Events, Compression Syndromes

The degree of invasiveness of a surgical procedure is not defined by the sum of incision lengths, but rather by the general physiological insult experienced by the patient. Intraabdominal transluminal endoscopy certainly creates new problems that do not have a role in conventional diagnostic or interventional endoscopy.

The physiology of pneumoperitoneum has been studied intensively in




Figure 8. ELITE is a universal training phantom for laparoscopic, endoscopic, and NOTES specific tasks. The female model is equipped with a realistic reproduction of intestinal organs and supports endoscopic examinations and training of complex transluminal procedures.

laparoscopy, but unknown is whether pneumoperitoneum during NOTES will behave in an identical fashion. In our own study, on-demand insufflation with a standard endoscopic light source/insufflator resulted in a marked increase and wide variation in intra-abdominal pressures throughout transgastric peritoneoscopy.⁵⁰ Although only fair hemodynamic changes were observed, major increases in inspiratory pressure suggest a need for stricter control of intra-abdominal hypertension. How far these results may be transferred to humans remains to be further investigated, but dedicated NOTES insufflators will certainly have a pressure control.

Other issues of current and future investigation are the use of CO₂ instead of air, the prevention of gas embolism, and other phenomena like thrombo-cytopenia.⁵¹ Advances in this field will not revolutionize natural orifice surgery, but will improve feasibility.

Training Other Providers

It is a peculiarity of NOTES that the cognitive abilities and manual skills of both an Endoscopist and of an experienced Laparoscopic Surgeon are required. Accordingly, the need for education and training is only possible in animals. Inorganic training systems [either mechanical or computer-based]⁵² provide training facilities either for laparoscopy or endoscopy, but not for hybrid surgery or NOTES. The first training manikin dedicated to education in NOTES is the "endoscopic/laparoscopic interdisciplinary training entity ELITE (CLA, Coburg, Germany). It offers to simulate standard access techniques (transoral, transanal, transvaginal) and perform current NOTES interventions (eg, peritoneoscopy, cholecystectomy, appendectomy) using the usual endoscopic instruments (Fig. 8).⁵³

However, the degree of immersion is physically limited in mechanic models. In the long run, computer-based learning environments for virtual reality have to be provided. As in minor access surgery, or endoscopy, they are indispensable to shorten the way from bench to bedside.⁵⁴

CONCLUSIONS

The theoretical concept of NOTES as another step toward completely non-traumatic surgery is certainly exciting. However, this vision remains far away

from becoming a reality.

Even though some reports on "scarless surgical procedures" have already been published, it is obvious that NOTES, using flexible endoscopy alone, is extremely difficult and may be applied in only exceptional cases. The use of additional, auxiliary transmural instruments, however, already offers a surgery without visible scars that may be a new alternative to conventional laparoscopic surgery in selected cases.

Further progress in biomedical engineering is predictable and, likewise, dedicated and most helpful new tools for NOTES can be expected. Accordingly, it is not a matter of why but when real NOTES will be available as a standard technique in modern surgery. In theory, even possible is that NOTES could substitute laparoscopy as the primary approach in the surgical treatment of various diseases, but more probably its main role will be that of a super low-invasive alternative to standard laparoscopy in select cases. **STI**

REFERENCES

1. ASGE/SAGES Working Group on Natural Orifice Transluminal Endoscopic Surgery, White Paper. *Gastrointest Endosc* 2006;63(2):199-203.
2. Baron TH. Natural orifice transluminal endoscopic surgery. *Br J Surg* 2007;94(1):1-2.
3. Bachman SL, Sporn E, Furrer JA, et al. Colonic sterilization for NOTES procedures-A comparison of two decontamination protocols. *SAGES 2008* (Abstract).
4. o Padoy N, Horn M, Feussner H, et al. Recovery of surgical workflow: A model based approach. *Int J CARS* 2007(Suppl):479-82.
5. Forgione A, Maggioni D, Sansonna F, et al. Transvaginal endoscopic cholecystectomy in human beings: preliminary results. *J Laparoendosc Adv Surg Tech* 2008;18(3):345-51.
6. Bingener J, Michalek J, van Sickle K, et al. Randomized blinded trial shows relative thrombocytopenia in natural orifice transluminal endoscopic surgery compared with standard laparoscopy in a porcine survival model. *Surg Endosc* 2008;22(9):2067-71.
7. Ramos AC, Murakami A, Galvão Neto M, et al. NOTES transvaginal video-assisted cholecystectomy: First series. *Endoscopy* 2008;40(7):572-5.
8. Can S, Fiolka A, Mayer H, et al. The mechatronic support system "HVSPS" and the way to NOTES. *Min Invasive Ther Allied Technol* 2008;17(6):341-5.
9. Chiu PW, Lau JY, Ng EK, et al. Closure of a gastrotomy after transgastric tubal ligation by using the Eagle Claw VII: A survival experiment in a porcine model (with video). *Gastrointest Endosc* 2008;68(3):554-9.
10. Burghardt J, Federlein M, Elling D, et al. Transvaginale Cholezystektomie-Erfahrungen mit einem neuen Zugangsweg. *CHAZ* 2008;9:23-6.
12. von Delius S, Feussner H, Henke J, et al. Submucosal endoscopy: A novel approach to en bloc endoscopic mucosal resection (with videos). *Gastrointest Endosc* 2007;66(4):753-6.
13. von Delius S, Gillen S, Doundoulakis E, et al. Comparison of transgastric access techniques for natural orifice transluminal endoscopic surgery. *Gastrointest Endosc* 2008;68(5):940-7.
14. von Delius S, Huber W, Feussner H. Effect of pneumoperitoneum on hemodynamics and inspiratory pressures during natural orifice transluminal endoscopic surgery (NOTES): An experimental, controlled study in an acute porcine model. *Endoscopy* 2007;39:854-9.
15. Delvaux G, Devroey P, De Waele B. Transvaginal removal of gallbladders with large stones after laparoscopic cholecystectomy. *Surg Laparosc Endosc* 1992;3(4):307-9.
16. Johnson E. Surgical simulators and simulated surgeons: Reconstituting medical practice and practitioners in simulations. *Soc Stud Sci* 2007;37(4):585-608.
17. Feuerstein M, Reichl T, Vogel J, et al. Magneto-optic tracking of a flexible laparoscopic ultrasound transducer for laparoscope augmentation. *Med Image Comput Comput Assist Interv Int Conf Med Image Comput Assist Interv* 2007;10(Pt 1):458-66.
18. Feussner H, Can S, Fiolka A, et al. Hybrid surgery—the way towards NOTES: The challenge for computer science; IEEE International Symposium on Biomedical Imaging: From Nano to Macro, Paris, 2008.
19. Feussner H. The operating room of the future: A view from Europe. *Sem Laparosc Surg* 2003;10(3):149-56.
20. Fong DG, Pai RD, Thompson CC. Transcolonic endoscopic abdominal exploration: A notes survival study in a porcine model. *Gastrointest Endosc* 2007;C5(2):312-8.
- 19 Fong DG, Ryou M, Pai RD, et al. Transcolonic ventral wall hernia repair mesh fixation in a porcine model. *Endoscopy* 2007;39(10):865-9.
21. Zornig C, Mofied H, Emmermann A, et al. Scarless cholecystectomy with combined transvaginal and transumbilical approach in a series of 20 patient. *Surg Endosc* 2008;22(6):27-1429.
22. Kantsevov SV, Jagannath SB, Niiyama H, et al. Endoscopic gastrojejunostomy with survival in a porcine model. *Gastrointest Endosc* 2005;62(2):287-92.
23. Jagannath SB, Kantsevov SV, Vaughn CA, et al. Peroral transgastric endoscopic ligation of fallopian tubes with long-term survival in a porcine model. *Gastrointest Endosc* 2005;61(3):449-53.
24. Gettman MT, Blute ML. Transvesical peritoneoscopy: Initial clinical evaluation of the bladder as a portal for natural orifice transluminal endoscopic surgery. *Mayo Clin Proc* 2007;82(7):843-5.
25. Kalloo AN, Singh VK, Jagannath SB, et al. Flexible transgastric peritoneoscopy: A novel approach to diagnostic and therapeutic inter-

- ventions in the peritoneal cavity. *Gastrointest Endosc* 2004;60(1):114-7.
26. Hausmann U, Feussner H, Ahrens P, et al. Endoluminal endosurgery: rivet application in flexible endoscopy. *Gastrointest Endosc* 2006;64(1):101-3.
27. Marks JM, Ponsky JL, Pearl JP, McGee MF. PEG "rescue": A practical NOTES technique. *Surg Endosc* 2007;21(5):816-9.
28. Hazey JW, Needleman BJ, Melvin WS. Transgastric instrumentation and bacterial contamination of the peritoneal cavity. SAGES Meeting, S044, 2007.
29. Herron DM, Marohn MA. A consensus document on robotic surgery. *Surg Endosc* 2008;22(2):313-25.
30. Hu B, Chung SC, Kawashima K, et al. Eagle Claw II: A novel endosuture device that uses a curved needle for major arterial bleeding: A bench study. *Gastrointest Endosc* 2005;62(2): 266-70.
31. Lima E, Rolanda C, Pêgo JM, et al. Transvesical endoscopic peritoneoscopy: A novel 5 mm port for intra-abdominal scarless surgery. *J Urol* 2006;176(2):802-5.
32. Bergstrom M, Ikeda K, Swain P, et al. Transgastric anastomosis by using flexible endoscopy in a porcine model. *Gastrointest Endosc* 2006;63(2):307-12.
33. Merrifield BF, Wagh MS, Thompson CC. Peroral transgastric organ resection: A feasibility study in pigs. *Gastrointest Endosc* 2006; 63(4):693-7.
34. Kirschniak A, Kratt T, Stüker D, et al. A new endoscopic over-the-scope clip system for treatment of lesions and bleeding in the GI tract: first clinical experiences. *Gastrointest Endosc* 2007;66(1):162-7.
35. Lima E, Henriques-Coelho T, Roland C, et al. Transvesical thoracoscopy: A natural orifice transluminal approach for thoracic surgery. *Surg Endosc* 2007;21(6):854-8.
36. Pai RD, Fong DG, Bundga ME, et al. Transcolonic endoscopic cholecystectomy: A NOTES survival study in a porcine model (with video). *Gastrointest Endosc* 2006;64(3): 428-34.
37. Tsin DA, Colombero LT, Lambeck J. Minilaparoscopy-assisted natural orifice surgery. *JLS* 2007;11(1):24-
38. Magno P, Giday SA, Dray X, et al. A new stapler based full thickness transgastric access closure: results from an animal pilot trial. *Endoscopy* 2007;39(10):876-80.
39. Martinsen TC, Bergh K, Waldum HL. Gastric juice: A barrier against infectious diseases. *Basic Clin Pharmacol Toxicol* 2005;96(2):94-102.
40. Mayer H, Nagy I, Knoll A, et al. Computer interfaces of a system for robotic heart surgery. Proceedings of the Second International Conference on Human-Computer Interaction, 2007.
41. McGee MF, Marks JM, Jin J, et al. Complete endoscopic closure of gastric defects using a full-thickness tissue plicating device. *J Gastrointest Surg* 2008;12(1):38-45.
42. McGee MF, Marks JM, Onders R, et al. Infectious implications in the porcine model of natural orifice transluminal endoscopic surgery (NOTES) with percutaneous endoscopic gastrostomy (PEG) tube closure. *Gastrointest Endosc* 2007;68(2):310-8.
43. McGee MF, Schomisch SJ, Marks JM, et al. Late phase TNF-alpha depression in natural orifice transluminal endoscopic surgery (NOTES) peritoneoscopy. *Surgery* 2008;143 (3):318-28.
44. Meining A, Wilhelm D, Burian M, et al. Development, standardization, and evaluation of NOTES cholecystectomy using a transsigmoid approach in the porcine model: An acute feasibility study. *Endoscopy* 2007;39(10):860-4.
45. Meireles OR, Kantsevov SV, Assumpcao LR, et al. Reliable gastric closure after natural orifice transluminal endoscopic surgery using a novel automated flexible stapling device. *Surg Endosc* 2008;22(7):1609-13.
46. Park PO, Bergstrom M, Ikeda K, et al. Experimental studies of transgastric gallbladder surgery: Cholecystectomy and cholecystogastric anastomosis. *Gastrointest Endosc* 2005; 61(4):601-6.
47. Narula VK, Hazey JW, Renton DB, et al. Transgastric instrumentation and bacterial contamination of the peritoneal cavity. *Surg Endosc* 2008;22(3):05-611.
48. Onders RP, McGee MF, Marks J, et al. Natural orifice transluminal endoscopic surgery (NOTES) as a diagnostic tool in the intensive care unit. *Surg Endosc* 2007;21(4):681-3.
49. Sumiyama K, Gostout CJ, Rajan E. Pilot study of the porcine uterine horn as an in vivo appendicitis model for development of endoscopic transgastric appendectomy. *Gastrointest Endosc* 2006;64(5):808-12.
50. Sumiyama K, Gostout CJ, Rajan E. Submucosal endoscopy with mucosal flap safety valve. *Gastrointest Endosc* 2007;65(1):688-94.
51. Penne J, Höller K, Krüger S, et al. NOTES3D: Endoscopes learn to see 3D; Basic Algorithms for a Novel Endoscope. In: Ranchor-das, A.H.; Araújo, H.; Vitriá J. (Eds.): VISAPP, Second International Conference on Computer Vision Theory and Applications (VISAPP Barcelona 8.-11.3.2007). Barcelona: Instic Press: 2007;134-9.
52. Perretta S, Dallemagne B, Coumaros D, Marescaux J. Natural orifice transluminal endoscopic surgery: Transgastric cholecystectomy in a survival porcine model. *Surg Endosc* 2008;22(4):1126-30.
53. Pham BV, Raju GS, Ahmed I, et al. Immediate endoscopic closure of colon perforation by using a prototype endoscopic suturing device: Feasibility and outcome in a porcine model. *Gastrointest Endosc* 2006; 64(1):113-9.
54. Zorron R, Maggioni LC, Pombo L, et al. NOTES transvaginal cholecystectomy: Preliminary clinical application. *Surg Endosc* 2008;22(2):542-547
55. Raju GS, Pham BV, Xiao SY. A pilot study of endoscopic closure of colonic perforations with endoclips in a swine model. *Gastrointest Endosc* 2005;62(5):791-5.
56. von Renteln D, Schmidt A, Riecken B, Caca K. Gastric full-thickness suturing during EMR and for treatment of gastric-wall defects (with video). *Gastrointest Endosc* 2008;67(4):738-44.
57. Rolanda C, Lima E, Pego JM. Third generation cholecystectomy by natural orifices: transgastric and transvesical combined approach. *Gastrointest Endosc* 2007;65(1): 111-7.
58. Sarker SK, Patel B. Simulation and surgical training. *Intl J Clin Practice* 2007;61(12): 2120-5.
59. Sporn E, Miedema BW, Bachmann SL, et al. Endoscopic colostomy closure after full thickness excision: comparison of T fastener versus multi-clip applicator. *Endoscopy* 2008;40(7):589-94.
60. Wagh MS, Merrifield BF, Thompson CC. Endoscopic transgastric abdominal exploration and organ resection: Initial experience in a porcine model. *Clin Gastroenterol Hepatol* 2005;3(9):892-6.
61. Sumiyama K, Gostout CJ, Rajan E, et al. Endoscopic full-thickness closure of large gastric perforations by use of tissue anchors. *Gastrointest Endosc* 2007;65:134-9.
62. Swanstrom LL, Kozarek R, Pasricha PJ, et al. Development of a new access device for transgastric surgery. *J Gastrointest Surg* 2005;9(8):1129-36.
63. Swanstrom LL, Whiteford M, Khanjee V. Developing essential tools to enable transgastric surgery. *Surg Endosc* 2008;22(3):600-4.
64. Thele F, Zygmunt M, Glitsch A, et al. How do gynecologists feel about transvaginal NOTES surgery? *Endoscopy* 2008;40(7):576-80.
65. Thompson CC, Ryou M, Rothstein RI, et al. Stomach-direct drive endoscopic system for endoluminal and NOTES applications. The DAVE project. 2008.
66. Voermans RP, Worm AM, van Berge Henegouwen MI, et al. In vitro comparison and evaluation of seven gastric closure modalities for natural orifice transluminal endoscopic surgery (NOTES). *Endoscopy* 2008;40(7): 595-601.
67. Vosburgh KG, Estépar RSJ. Natural orifice transluminal endoscopic surgery (NOTES): An opportunity for augmented reality. *Stud Health Technol Inform* 2007;125:485-90.
68. Hazey JW, Narula VK, Renton DB, et al. Natural-orifice transgastric endoscopic peritoneoscopy in humans: Initial clinical trial. *Surg Endosc* 2007;22(1):16-20.
69. Wagh MS, Merrifield BF, Thompson CC. Survival studies after endoscopic transgastric oophorectomy and tubectomy in a porcine model. *Gastrointest Endosc* 2006; 63(3):473-8.
70. Wilhelm D, Meining A, von Delius S, et al. An innovative, safe and sterile sigmoid access (ISSA) for NOTES. *Endoscopy* 2007;39:401-6.
71. Zornig C, Emmermann A, von Waldenfels HA, Felixmüller C. Colpotomy for specimen retrieval in laparoscopic surgery. *Chirurg* 1994;65(10):883-5.
72. Feussner H, Gillen S, Hagen M, et al. Assessment of current gastrointestinal occlusion techniques for NOTES. *Endoskopie Heute* 2008 (In Press).
73. Lehman AC, Dumpert J, Wood BS, et al. Natural orifice cholecystectomy using a miniature robot. *Surg Endosc* 2008;22:S157.
- exploration: A NOTES survival study in a porcine model. *Gastrointest Endosc* 2007; 65(2):312-8.